

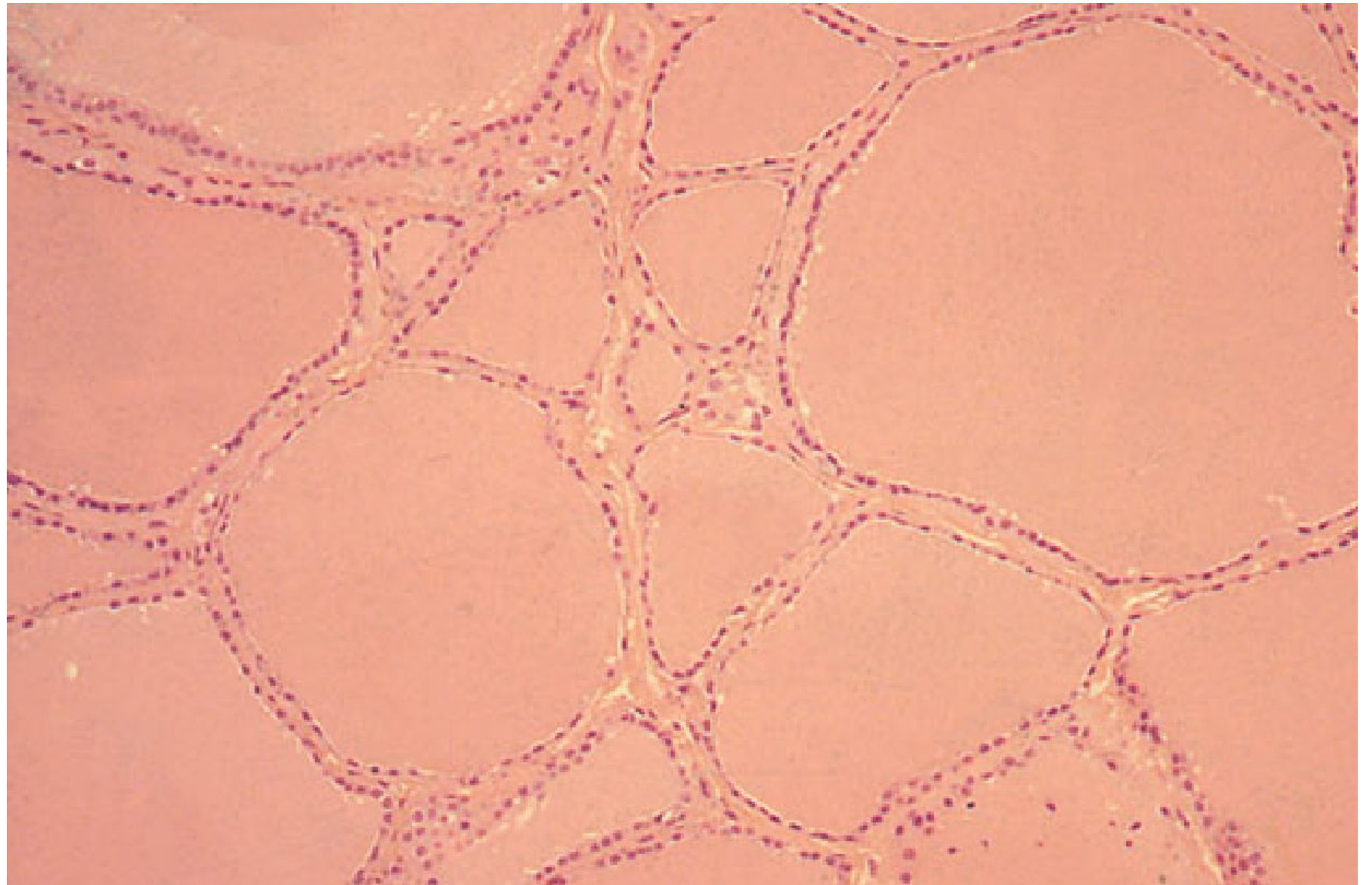
# The thyroid gland

## Surgical anatomy

The normal gland weighs 20—25 g. The functioning unit is the **lobule** supplied by a single arteriole and consisting of 24—40 follicles which are lined by cuboidal epithelium. The resting follicle contains colloid in which thyroglobulin is stored.

**The arterial supply** is rich, and extensive anastomoses occur between the main thyroid arteries and branches of tracheal and oesophageal arteries.

There is an **extensive lymphatic network** within the gland. Although some lymph channels pass directly to the deep cervical nodes, the subcapsular plexus drains principally to the juxtathyroid nodes, i.e. pretracheal and paratracheal nodes, and nodes on the superior and inferior thyroid veins, and then to the deep cervical and mediastinal group of nodes.



# **Ectopic thyroid and anomalies of the thyroglossal tract**

Some residual thyroid tissue along the course of the thyroglossal tract is not uncommon, and may be lingual, cervical or intrathoracic. Very rarely the whole gland is ectopic.

## **Lingual thyroid**

This forms a rounded swelling at the back of the tongue at the foramen caecum and it may represent the only thyroid tissue present. It may cause dysphagia, impairment of speech, respiratory obstruction or haemorrhage. It is best treated by full replacement with thyroxine when it should get smaller, but excision or ablation with radioiodine is sometimes necessary.

## Median (thyroglossal) ectopic thyroid

This forms a swelling in the upper part of the neck and is usually mistaken for a thyroglossal cyst. Again, this may be the only normal thyroid tissue present.

## Lateral aberrant thyroid

**There is no evidence that aberrant thyroid tissue ever occurs in a lateral position.** 'Normal thyroid tissue' found laterally, separate from the thyroid gland, must be considered and treated as a metastasis in a cervical lymph node from an occult thyroid carcinoma, almost invariably of papillary type.

Struma ovarii is not ectopic thyroid tissue, but part of an ovarian teratoma. Very rarely, **neoplastic change** occurs or **hyperthyroidism** develops.

# Thyroglossal cyst

This may be present in any part of the thyroglossal tract. The common situations, in order of frequency, are beneath the hyoid, in the region of the thyroid cartilage, and above the hyoid bone. Such a cyst occupies the midline, except in the region of the thyroid cartilage, where the thyroglossal tract is pushed to one side, usually to the left. It is to be remembered that **the swelling moves upwards on protrusion of the tongue as well as on swallowing because of the attachment of the tract to the foramen caecum.**

A thyroglossal cyst should be excised because infection is inevitable, owing to the fact that the wall contains nodules of lymphatic tissue which communicate by lymphatics with the lymph nodes of the neck. An infected cyst is often mistaken for an abscess and incised, which is one way in which a thyroglossal fistula arises.

## **Thyroglossal fistula**

Thyroglossal fistula is never congenital: it follows infection or inadequate removal of a thyroglossal cyst. Characteristically the cutaneous opening of such a fistula is drawn upwards on protrusion of the tongue. A thyroglossal fistula is lined by columnar epithelium, discharges mucus, and is the seat of recurrent attacks of inflammation.

## **Treatment**

Because the thyroglossal tract is so closely related to the body of the hyoid bone, this central part must be excised, together with the cyst or fistula, or recurrence is certain. When the thyroglossal tract can be traced upwards towards the foramen caecum, it must be excised with the central section of the body of the hyoid bone, and a central core of lingual muscle (Sistrunk's operation).



## Physiology of the thyroid

The hormones tri-iodothyronine (T3) and thyroxine (T4) are bound to thyroglobulin within the colloid. Synthesis within the thyroglobulin complex is controlled by several enzymes, in distinct steps:

- Trapping of inorganic iodide from the blood;
- Oxidation of iodide to iodine;
- Binding of iodine with tyrosine to form iodotyrosines;
- Coupling of mono-iodotyrosines and di-iodotyrosines to form T3 and T4
- When hormones are required the complex is resorbed into the cell and thyroglobulin broken down; T3 and T4 are liberated and enter the blood where they are bound to serum proteins: **albumin** and **thyroxine binding globulin (TBG)** and **prealbumin (TBPA)**. A small amount of hormone remains free in the serum in equilibrium with the protein-bound hormone and is biologically active. The metabolic effects of the thyroid hormones are due to unbound free T4 and T3 (0.03 per cent and 0.3 per cent of the total circulating hormones, respectively). T3 is quick acting (within a few hours) whereas T4 acts more slowly (4—14 days). T3 is the more important physiological hormone and is also produced in the periphery by conversion from T4



## **The pituitary thyroid axis**

Synthesis and liberation of thyroid hormones from the thyroid is controlled by thyroid-stimulating hormone (**TSH**) from the anterior pituitary. Secretion of TSH depends upon the level of circulating thyroid hormones and is modified in a classic negative feedback manner. In hyperthyroidism, where hormone levels in the blood are high, TSH production is suppressed whereas in hypothyroidism it is stimulated. Regulation of TSH secretion also results from the action of thyrotrophin-releasing hormone (TRH) produced in the hypothalamus.

## **Thyroid stimulating antibodies**

A family of IgG immunoglobulins binds with TSH receptor sites (TRAbs) and activate TSH receptors on the follicular cell membrane. **They have a more protracted action than TSH (16—24 hours versus 1.5—3hours)** and are responsible for virtually all cases of thyrotoxicosis not due to autonomous toxic nodules. Serum concentrations are very low and not routinely measured.

# Tests of thyroid function

## Serum thyroid hormones

**Serum TSH.** TSH levels can be measured accurately down to very low serum concentrations and if the serum TSH level is in the normal range it is redundant to measure the T3 and T4 levels. In the ***euthyroid state***, T3, T4 and TSH levels will all be within the normal range. ***Florid thyroid failure*** results in depressed T3 and T4 levels with gross elevation of the TSH. ***Incipient or developing thyroid failure*** is characterised by low normal values of T3 and T4 and elevation of the TSH. ***In toxic states*** the TSH level is suppressed and undetectable. Thyroxine (T4) and tri-iodothyronine (T3) are transported in plasma bound to specific proteins (thyroxine-binding globulin, TBG). Only a small fraction of the total (0.03 per cent of T4 and 0.3 per cent of T3) is free and physiologically active. Assays of both total and free hormone are available **but the total values depend on the level of circulating proteins** which are affected by the level of circulating oestrogen. Thus, pregnant women and those on the oral contraceptive pill have elevated total T4 and T3 levels without evidence of toxicity. The free hormone levels are unaffected. Similarly some patients have low levels of TBG either as a primary phenomenon or secondary to a reduction in serum protein levels as a result of **systemic or liver disease** and the total level of circulating hormone may be low.

# Thyroid investigations

## Essential

- Serum: TSH (T3 and T4 if abnormal); thyroid autoantibodies
- FNAC of palpable discrete swellings

## Optional

- Serum calcium
- Serum calcitonin (carcinoembryonic antigen may be used as an alternative screening test for medullary cancer)
- Imaging: **chest radiograph** and thoracic inlet if tracheal deviation/retrosternal goitre; **ultrasound, CT and MRI scan** for known cancer, some reoperations and some retrosternal goitres; **isotope scan** if discrete swelling and toxicity coexist.

For these reasons the free levels are more meaningful. **Highly accurate radioimmunoassays** of free T3 and free T4 are now routine. T3 toxicity (with a normal T4) is a distinct entity and may only be diagnosed by measuring the serum T3, although a suppressed TSH level with a normal T4 is suggestive.

An appropriate combination is to establish the functional thyroid status at initial assessment, with TSH supplemented by free T4, and T3 evaluation when TSH is abnormal.

### **Normal thyroid functional state**

<b>TSH</b>	<b>(0.3–3.3 mU l<sup>-1</sup>)</b>
<b>Free T4</b>	<b>(10–30 nmol l<sup>-1</sup>)</b>
<b>Free T3</b>	<b>(3.5–7.5 μmol l<sup>-1</sup>)</b>

## **Isotope scanning**

The uptake by the thyroid of a low dose of either radiolabelled iodine ( $^{123}\text{I}$  iodine) or technetium-99m ( $^{99\text{m}}\text{Tc}$ , which is normally taken up like  $^{123}\text{I}$ ) will **demonstrate the distribution of activity in the whole gland**. This test is inappropriate for distinguishing benign from malignant lesions because the majority (80 per cent) of cold swellings is benign and some (5 per cent) functioning or warm swellings will be malignant. Its principal value is in the toxic patient with a nodule or nodularity of the thyroid. Localisation of over activity in the gland will differentiate between a toxic nodule with suppression of the remainder of the gland and toxic multinodular goitre with several areas of increased uptake. This is for therapeutic purposes.

**Remember : Routine isotope scanning is unnecessary**

Whole body scanning is used to demonstrate metastases but the patient must have all normally functioning thyroid tissue ablated either by surgery or by ablation with high-dose radioiodine before the scan is performed because thyroid cancer cannot compete with normal thyroid tissue in the uptake of iodine.

## **Thyroid autoantibodies**

Serum titres of antibodies against **thyroid peroxidase** and **thyroglobulin** are useful in determining the cause of thyroid dysfunction and swellings. Autoimmune thyroiditis may be associated with thyroid toxicity, failure or euthyroid goitre.

# Hypothyroidism

## Cretinism (foetal or infantile hypothyroidism)

**Sporadic Cretinism** is due to complete or near complete failure of thyroid development (partial failure causes juvenile myxoedema): the parents and other children may be perfectly normal. **In endemic areas**, goitrous cretinism is common, and is due to maternal and foetal iodine deficiency. Immediate diagnosis and treatment with thyroxine within a few days of birth are essential if physical and mental development are to be normal, or if further deterioration is to be prevented when damage has already occurred in utero. Women under treatment with anti-thyroid drugs may give birth to a hypothyroid infant.

## Adult hypothyroidism

The term myxoedema should be reserved for severe thyroid failure and not applied to the much commoner mild thyroid deficiency.



## The signs of thyroid deficiency are:

- Bradycardia;
- Cold extremities;
- Dry skin and hair;
- Periorbital puffiness;
- Hoarse voice;
- Bradykinesia-slow movements;
- Delayed relaxation phase of ankle jerks.

## The symptoms are:

- Tiredness;
- Mental lethargy;
- Cold intolerance;
- Weight gain;
- Constipation;
- Menstrual disturbance;
- Carpal tunnel syndrome.

Comparison of the facial appearance with a previous photograph may be helpful.

If the signs and symptoms of hypothyroidism are accentuated. *The facial appearance is typical, and there is often supraclavicular puffiness, a malar flush and a yellow tinge to the skin.*

## Thyroid function tests

Thyroid function tests show low T4 and T3 levels with a high TSH (except in the rare event of pituitary failure). High serum titres of antithyroid antibodies are characteristic of autoimmune disease.

## Treatment

Oral thyroxine (0.10—0.20 mg) as a single daily dose (because of its prolonged action) is curative. Caution is required in the elderly or those with cardiac disease and the replacement dose is then commenced at 0.05 mg daily and cautiously increased. If a rapid response is required, tri-iodothyronine (20 µg three times a day) may be used.

**Myxoedema coma** occurs in neglected cases and carries a high mortality; the body temperature is low and the patient must be warmed slowly: 1 g of intravenous hydrocortisone (in divided doses) should be given daily and intravenous tri-iodothyronine in slowly increasing doses.

# **Autoimmune thyroiditis**

The so-called primary or atrophic myxoedema is now considered to be an autoimmune disease similar to chronic lymphocytic (Hashimoto's) thyroiditis but 'without goitre formation from TSH stimulation. Because of the delay in diagnosis the hypothyroidism is usually much more severe than in goitrous autoimmune thyroiditis.

# Dyshormonogenesis and goitrogens

## Dyshormonogenesis

Genetically determined deficiencies in the enzymes controlling the synthesis of thyroid hormones, *if severe*, are responsible for goitre formation with hypothyroidism. *If of moderate degree*, a simple (euthyroid) goitre results.

**Similarly goitrogens** may produce goitre with, or without, hypothyroidism.

When thyroglobulin is broken down, uncoupled iodotyrosines are liberated as well as T3 and T4. They are broken down by the enzyme dehalogenase and the iodine retained within the thyroid. If **dehalogenase** is deficient, iodotyrosines pass into the blood, and are excreted in the urine and this may result in iodine deficiency and goitre formation. Another classic example of dyshormonogenesis is ***Pendred's syndrome***, where goitre is associated with congenital deafness. This is due to a deficiency of **peroxidase**, the enzyme responsible for organification of trapped iodine. Defects in thyroglobulin synthesis are also recognised in dyshormonogenesis.

# Thyroid enlargement

The normal thyroid gland is impalpable. The term goitre is used to describe generalised enlargement of the thyroid gland. A ***discrete swelling*** (nodule) in one lobe with no palpable abnormality elsewhere is termed an **isolated** (or **solitary**) swelling. Discrete swellings with evidence of abnormality elsewhere in the gland are termed **dominant**.

# Classification of thyroid swellings:

## *Simple goitre (euthyroid)*

- Diffuse hyperplastic
- Physiological
- Pubertal
- Pregnancy
- Multinodular goitre

## *Toxic*

- Diffuse Graves' disease
- Multinodular
- Toxic adenoma

## *Neoplastic*

- Benign
- Malignant

## *Inflammatory*

- Autoimmune
- Chronic lymphocytic thyroiditis (Hashimoto's disease)
- Granulomatous
- De Quervain's thyroiditis
- Fibrosing
- Riedel's thyroiditis
- Infective
- Acute (bacterial thyroiditis, viral thyroiditis, 'subacute thyroiditis')
- Chronic (tuberculous, syphilitic)
- Other
- Amyloid



# Simple goitre

## Aetiology

Simple goitre may develop as a result of stimulation of the thyroid gland by **TSH**, either as a result of **inappropriate secretion** from a microadenoma in the anterior pituitary (which is rare), or in response to a **chronically low level of circulating thyroid hormones**. The most important factor in endemic goitre is dietary deficiency of iodine but defective hormone synthesis probably accounts for many sporadic goitres. TSH is not the only stimulus to thyroid follicular cell proliferation and other growth factors including immunoglobulins exert an influence.

## **Iodine deficiency**

The daily requirement of iodine is about 0.1—0.15 mg. In nearly all districts where simple goitre is endemic, there is a very low iodide content in the water and food.

Although iodides in food and water may be adequate, **failure of intestinal absorption** may produce iodine deficiency.

## **Defective hormone synthesis**

### **Enzyme deficiency/dyshormonogenesis**

It is probable that enzyme deficiencies of varying severity are responsible for many sporadic goitres, i.e. in nonendemic areas. There is often a family history suggesting a genetic defect. Environmental factors may compensate in areas of high iodine intake, for example goitre is almost unknown in Iceland where the fish diet is rich in iodine. Similarly a low intake of iodine encourages goitre formation in those with a metabolic predisposition.

# Goitrogens

Well-known goitrogens are the 1) vegetables of the brassica family (cabbageقرنابيط , kaleكرنب) which contain **thiocyanate**, 2) drugs such as para-aminosalicylic acid (PAS) and, 3) antithyroid drugs. **Thiocyanates and perchlorates interfere with iodide trapping**; **carbimazole and thiouracil compounds interfere with the oxidation of iodide and the binding of iodine to tyrosine.**

Surprisingly enough, iodides in large quantities are goitrogenic because they inhibit the organic binding of iodine and produce an iodide goitre.

# The natural history of simple goitre

*Stages in goitre formation are:*

- **Persistent growth stimulation** causes diffuse hyperplasia; all lobules are composed of active follicles and iodine uptake is uniform. This is a diffuse hyperplastic goitre, which may persist for a long time but is reversible if stimulation ceases;
- Later, as a result of **fluctuating stimulation**, a mixed pattern develops with areas of active lobules and areas of inactive lobules;
- Active lobules become more vascular and hyperplastic until haemorrhage occurs, causing **central necrosis** and leaving only a surrounding ring of active follicles;
- Necrotic lobules coalesce to form nodules filled with either iodine-free colloid or a mass of new but inactive follicles;
- Continual repetition of this process results in a nodular goitre. **Most nodules are inactive and active follicles are present only in the internodular tissue.**

# Diffuse hyperplastic goitre

Diffuse hyperplasia corresponds to the first stages of the natural history. The goitre appears in childhood in endemic areas but, in sporadic cases, it usually occurs at puberty when metabolic demands are high —puberty goitre. If TSH stimulation ceases, the goitre may regress, but tends to recur later at times of stress such as pregnancy. The goitre is soft, diffuse and may become large enough to cause discomfort. A colloid goitre is a late stage of diffuse hyperplasia when TSH stimulation has fallen off and when many follicles are inactive and full of colloid.

# Nodular goitre

Nodules are usually multiple, forming a multinodular goitre. Occasionally, only one macroscopic nodule is found, but microscopic changes will be present throughout the gland:

This is one form of a clinically solitary nodule. Nodules may be colloid or cellular, and cystic degeneration and haemorrhage are common, as is subsequent calcification. Nodules appear early in endemic goitre and later (between 20 and 30 years) in sporadic goitre, although the patient may be unaware of the goitre until the late 40s or 50s. All types of simple goitre are far more common in the female than in the male and the presence of oestrogen receptors in normal thyroid tissue and in nodular goitre is relevant.

## Diagnosis is usually straightforward

*The patient is euthyroid*: the nodules are palpable and often visible; they are smooth, usually firm and not hard, and the goitre is painless and moves freely on swallowing. Hardness and irregularity, due to calcification, may simulate carcinoma. **A painful nodule, sudden appearance or rapid enlargement of a nodule raises suspicion of carcinoma but is usually due to haemorrhage into a simple nodule.** Differential diagnosis from autoimmune thyroiditis may be difficult.

## Investigations

Tests of **thyroid function** are necessary to exclude mild hyperthyroidism, and the estimation of titres of **thyroid antibodies** to differentiate from autoimmune thyroiditis. **Plain radiographs** of the chest and thoracic inlet may show calcification and tracheal deviation or compression.



# Complications

- Tracheal obstruction is due to gross lateral displacement, or compression in a lateral or anteroposterior plane by retrosternal extension of the goitre. Acute respiratory obstruction may follow haemorrhage into a nodule impacted in the thoracic inlet.

- **Secondary thyrotoxicosis**

Figures as high as 30 per cent have been suggested.

- **Carcinoma**

Which is usually of follicular pattern. Reported from endemic areas.

# Prevention and treatment of simple goitre

**In endemic areas**, the incidence of goitre has been strikingly reduced by the introduction of iodised salt.

In the early stages a hyperplastic goitre may regress if thyroxine is given in a dose of 0.15—0.2 mg daily for a few months.

The nodular stage of simple goitre is irreversible. Most patients with multinodular goitre are asymptomatic and do not require operation. **Operation may be indicated in**

- 1) Cosmetic grounds if the goitre is unsightly.
- 2) Retrosternal extension with actual or incipient tracheal compression
- 3) Presence of a dominant area of enlargement which may be neoplastic.

## **There is a choice of surgical treatment:**

- a) total thyroidectomy with immediate and life-long replacement of thyroxine; or
- b) some form of partial resection to conserve sufficient functioning thyroid tissue to subserve normal function whilst eliminating the risk of hypoparathyroidism which accompanies total thyroidectomy. Partial resection aims to remove the bulk of the gland, leaving up to 8 g of relatively normal tissue in each remnant.
- c) More often, however, the multinodular change is asymmetrically distributed, with one lobe more significantly involved than the other. Under these circumstances total lobectomy on the more affected side is the appropriate management with either subtotal resection or no intervention on the less affected side..

In many cases the causative factors persist and recurrence is likely. **Reoperation** for recurrent nodular goitre is more difficult and hazardous and for this reason many thyroid surgeons favour total thyroidectomy in younger patients.

When a unilateral lobectomy alone has been performed for asymmetric goitre, reoperation is straightforward should it become necessary on the remaining lobe.

**After subtotal resection** it has been customary to give thyroxine to suppress TSH secretion with the aim of preventing recurrence.

The end

of

the first lecture